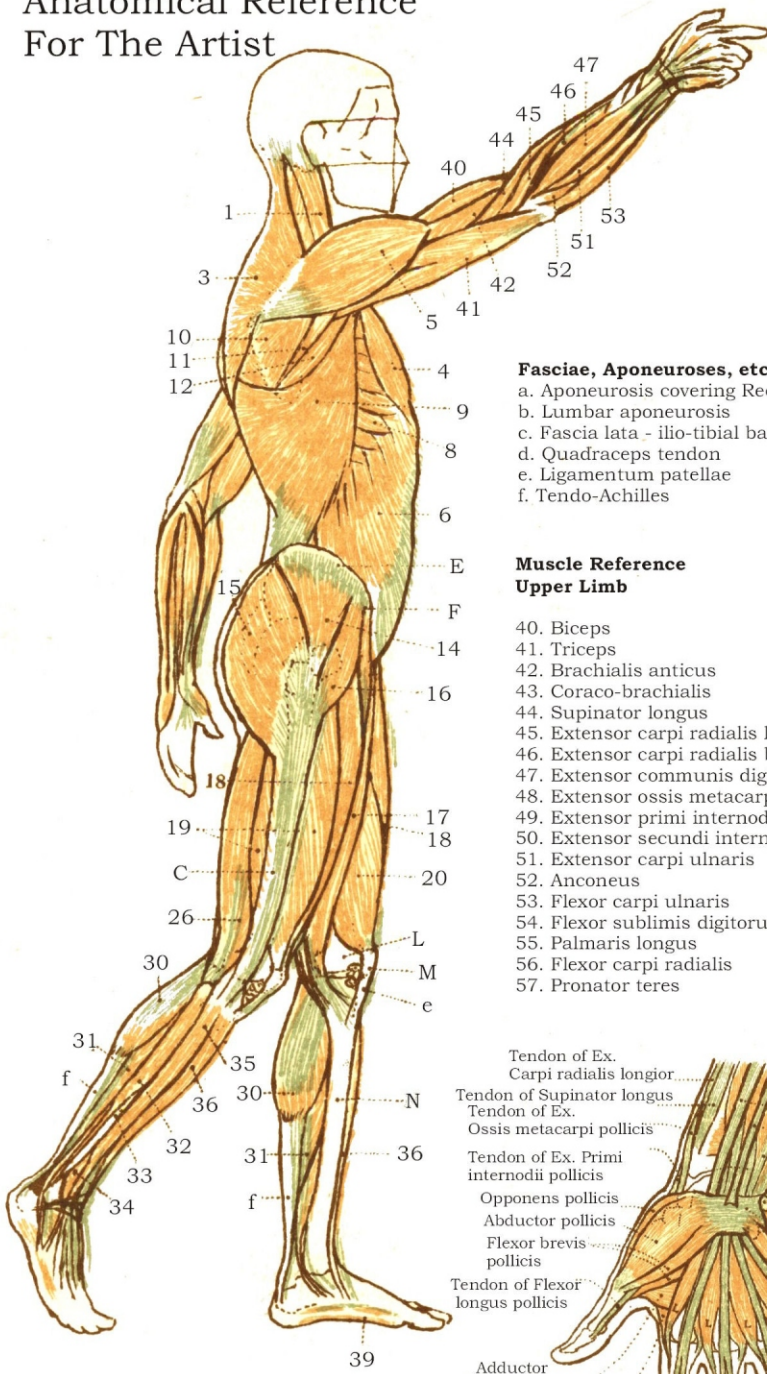


Anatomical Reference For The Artist



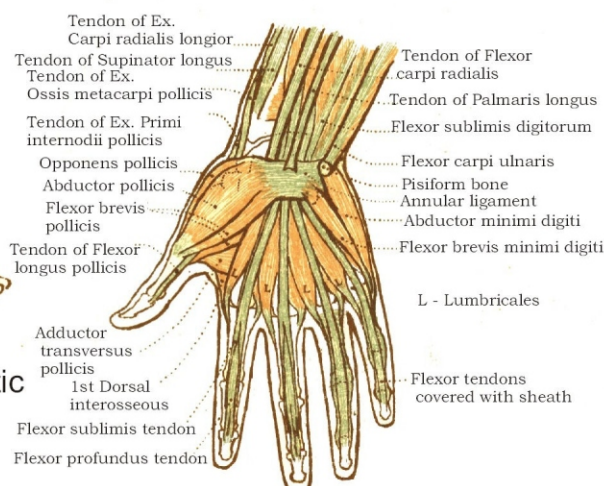
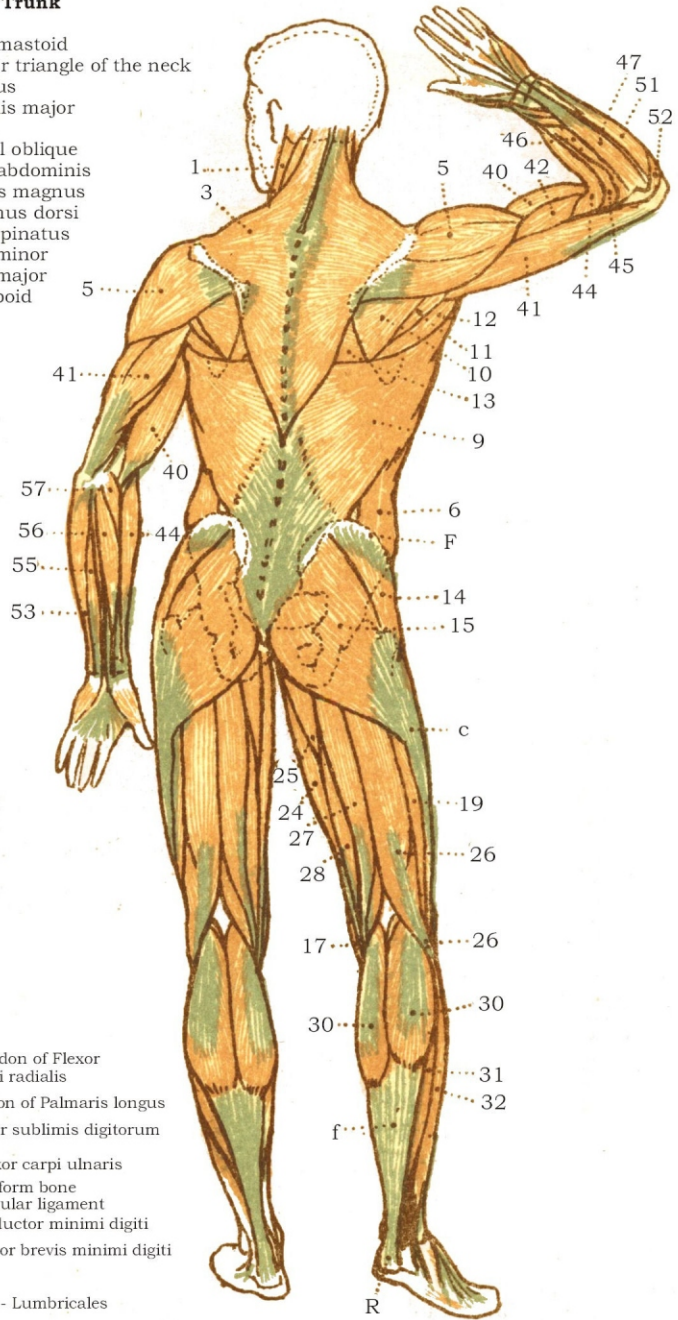
Muscle Reference Head and Trunk

1. Sterno-mastoid
2. Posterior triangle of the neck
3. Trapezius
4. Pectoralis major
5. Deltoid
6. External oblique
7. Rectus abdominis
8. Serratus magnus
9. Latissimus dorsi
10. Infra-spinatus
11. Teres minor
12. Teres major
13. Rhomboid

- Fasciae, Aponeuroses, etc.**
- a. Aponeurosis covering Rectus
 - b. Lumbar aponeurosis
 - c. Fascia lata - ilio-tibial band
 - d. Quadriceps tendon
 - e. Ligamentum patellae
 - f. Tendo-Achilles

Muscle Reference Upper Limb

40. Biceps
41. Triceps
42. Brachialis anticus
43. Coraco-brachialis
44. Supinator longus
45. Extensor carpi radialis longior
46. Extensor carpi radialis brevior
47. Extensor communis digitorum
48. Extensor ossis metacarpi pollicis
49. Extensor primi internodii pollicis
50. Extensor secundi internodii pollicis
51. Extensor carpi ulnaris
52. Anconeus
53. Flexor carpi ulnaris
54. Flexor sublimis digitorum
55. Palmaris longus
56. Flexor carpi radialis
57. Pronator teres



www.DCFirst.com Chiropractic Resources for Doctors, Students and Patients.

Copyright 2010 www.AnatomicalPrints.com

